Orthodontic Intrusion of Posterior Teeth Using Dental Implant Anchorage

GIULIO ALESSANDRI BONETTI, MD, DDS
SILVIA VERGANTI, DDS
MATTEO ZANARINI, DDS
EUGENIO GRAZIANI, MD, DDS

Premature loss of posterior teeth due to caries or periodontal disease can quickly lead to extrusion of the opposing teeth if immediate prosthetic replacement is not performed.[1] When the extrusion is caused by infraclusion, occlusal interferences during lateral excursion must be eliminated. Grinding the crown is an efficient way to correct molar extrusion, but it requires initial endodontic treatment if the enamel loss will extend as far as the dentin.

A more conservative treatment approach involves orthodontic intrusion of the extruded tooth. Most methods of preprosthetic intrusion, however, result in reciprocal extrusive movement of the anchorage teeth.[2-5] The present article describes orthodontic intrusion using an adjacent dental implant as anchorage.

Fig. 1 C-shaped fixed intrusion appliance positioned on cast.

Fig. 2 Case 1. Patient with extruded mandibular right second premolar before treatment (radiograph taken before implant placement).

Drs. Bonetti and Graziani are researchers and Drs. Verganti and Zanarini are residents, Department of Orthodontics, School of Dentistry, University of Bologna, Via S. Vitale 59, 40125 Bologna, Italy. E-mail Dr. Bonetti at alessandribonetti @libero.it.

Dr. Bonetti

Dr. Verganti

Dr. Zanarini

Dr. Graziani

Appliance Design

The anchorage element is a rigid, C-shaped piece of stainless steel that is connected to an osseointegrated implant with an abutment screw. Its arms extend around the lingual and buccal surfaces of the extruded tooth; each arm has two gingival hooks (Fig. 1). The active element, a 3⁄16", 5oz elastic, is stretched between the hooks across the extruded tooth's occlusal surface. The elastic exerts a light, continuous vertical force close to the tooth's center of resistance, producing mostly axial tooth

Fig. 3 Case 1. Intrusion appliance in place, with composite buttons bonded to occlusal surface to stabilize elastic.

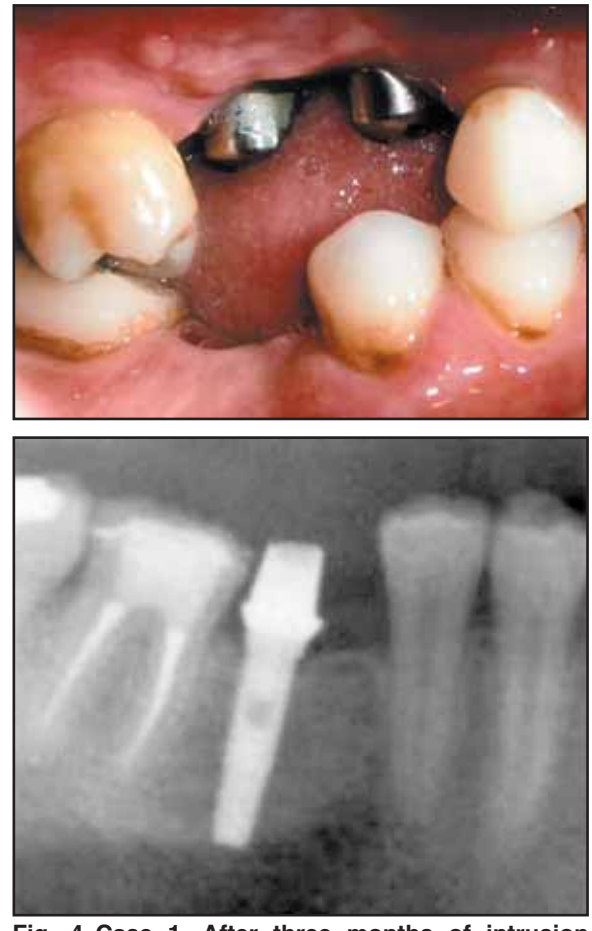

Fig. 4 Case 1. After three months of intrusion (photograph taken after removal of abutment for placement of prosthesis).

movement with no lingual or buccal tipping. The elastic is stabilized with composite attachments bonded to the tooth's occlusal surface.

Case 1

An adult patient presented with an extruded mandibular right second premolar due to loss of the opposing teeth. The patient had a prosthetic implant in place of the missing mandibular right first molar (Fig. 2). An intrusion appliance was constructed as described above and placed on the extruded tooth (Fig. 3). Three months later, the extrusion had been corrected, and the patient was ready for prosthetic rehabilitation, with no need for grinding of the crown (Fig. 4).

Fig. 5 Case 2. Patient with extruded maxillary right second molar before treatment.

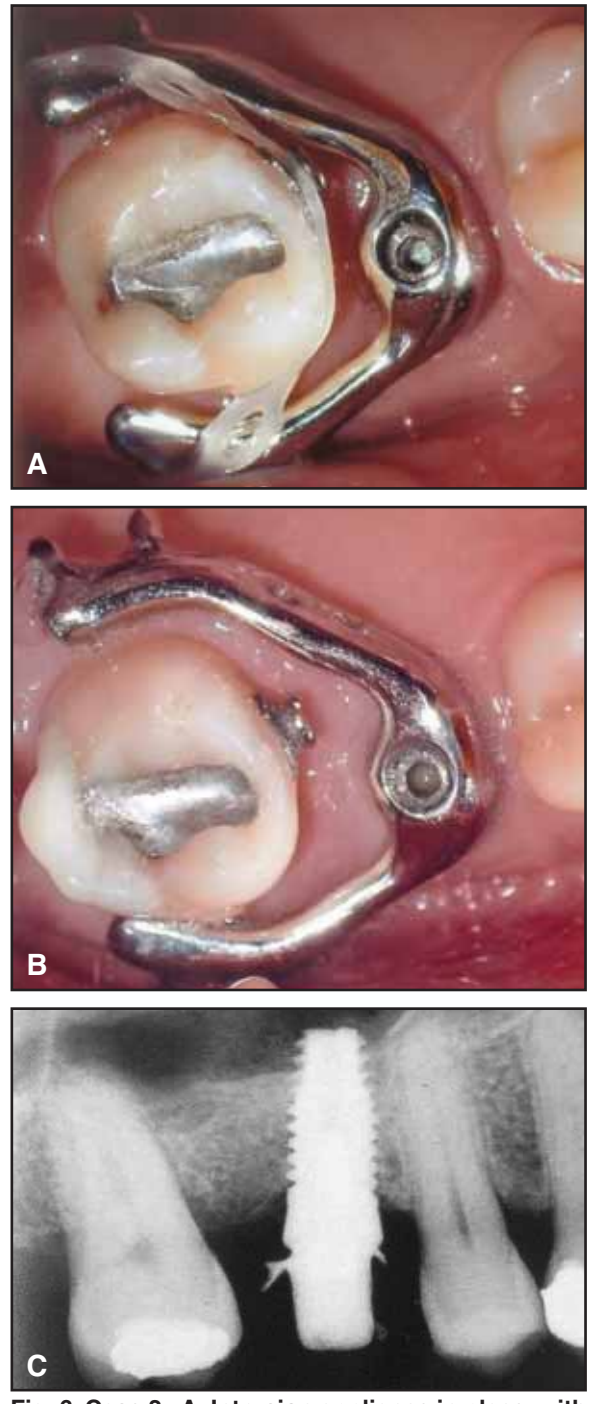

Fig. 6 Case 2. A. Intrusion appliance in place, with bonded button and elastic chain used to upright mesially inclined molar. B. After two months of uprighting. C. After three months of intrusion.

Case 2

An adult patient presented with an extruded and mesially inclined maxillary right second molar due to the loss of opposing and adjacent teeth; a prosthetic implant had been inserted in place of the missing maxillary right first molar (Fig. 5). An intrusion appliance was placed on the extruded tooth, and a button was bonded to the mesial surface for uprighting with an elastic chain (Fig. 6). After two months of uprighting and three months of intrusion, the patient was ready for prosthetic rehabilitation (Fig. 7).

Discussion

The technique described here can be used to intrude any overerupted molar or premolar that lies adjacent to an edentulous site with a current or planned dental implant. The extrusion can generally be corrected within about three months. The implant provides excellent anchorage control, with no need for banding of other teeth. Although the patient has to change the elastic, the device is well accepted because of its relative comfort, small size, and ease of cleaning.

Fig. 7 Case 2. Prosthetic replacement of missing teeth.

REFERENCES

1. Craddock, H.L.: An investigation of overeruption of posterior teeth with partial occlusal contact, J. Oral Rehab. 34:246-250, 2007.
2. Bonetti, G.A. and Giunta, D.: Molar intrusion with a removable appliance, J. Clin. Orthod. 30:434-437, 1996.
3. Chun, Y.S.; Woo, Y.J.; Row, J.; and Jung, E.J.: Maxillary molar intrusion with the Molar Intrusion Arch, J. Clin. Orthod. 34:90-93, 2000.
4. Hwang, H.S. and Lee, K.H.: Intrusion of overerupted molars by corticotomy and magnets, Am. J. Orthod. 120:209-216, 2001.
5. Armbruster, P.; Sheridan, J.J.; and Nguyen, P.: An Essix intrusion appliance, J. Clin. Orthod. 37:412-416, 2003.